

Retrospective study of Unstable Volar Barton Fracture treated by External Fixator

Bhoj Raj Adikhari*, Rajesh Chaudhary**, Badri Rijal**, Bhadra Hamal**

*Associate Professor, Department of Orthopaedics & Trauma Surgery, National Academy of Medical Sciences, Bir Hospital, Kathmandu, Nepal, **Assistant Professor, Department of Orthopaedics & Trauma Surgery, National Academy of Medical Sciences, Bir Hospital, Kathmandu, Nepal

ABSTRACT

INTRODUCTION: Volar Barton fracture is a common problem among the distal radius fracture. Volar articular margin is displaced and inherently unstable. External fixator is well established for the stabilization of the distal radius fracture in terms of stability, functional recovery and operative complications.

METHOD: This retrospective study was carried out in the department of Orthopedics & Trauma Surgery, National Trauma Center; Kathmandu, from March 2016 to September 2018. Within this period, 38 patients of unstable distal radius fractures were selected as per inclusion and exclusion criteria.

RESULT: In the final follow-up; 26.3% had excellent scores, 60.5% had good scores and 13.2% had fair scores on the basis of anatomical outcome. However, 90% had satisfactory functional outcomes on the basis of modified Mayo's wrist scoring system.

CONCLUSION: The external fixator was found to be an effective technique of fixation in displaced unstable volar Barton fracture; as it maintained articular congruity, radial length and alignment.

KEY WORDS: Distal radius, External fixator, Modified Mayo wrist score, Volar Barton Fracture.

INTRODUCTION

Fracture of distal radius is a spectrum of ranging from simple fracture requiring conservative management including cast application to complex multi-fragmented fracture dislocation, requiring surgical intervention. However, distal radius fracture involves the radio carpal joint and or the distal radio ulnar joint. These require an anatomical reduction of the joint surface in order to reduce the incidence of post traumatic arthritis and to achieve a successful functional outcome. Therefore intra articular fracture of Barton's, which is difficult to reduce in closed method, requires operative treatment including external fixator. The articular injuries are more frequently comminuted and unstable, and therefore less suitable for more traditional methods

of closed reduction and cast immobilization. However, skeletal fixation and re-alignment of fracture fragments are the better option.

Unstable volar Barton fracture requires closed reduction followed by external fixation or open reduction and plating. Several authors reported that, external fixator restores the articular congruity efficiently in unstable volar Barton fracture.^{1,2} If fractures are not reduced anatomically, intra-articular displacements are not corrected which may affect the surgical outcome.³⁻⁵ Therefore, surgical outcome depends on the anatomical reduction of fractures in spite of applied fixation techniques. The advantage of external fixator is the capability to rearrange the major displaced fracture fragments.

External fixation method is widely used procedure along with angle stable screws or pegs that offer stability and a safe approach for the unstable volar Barton fracture. Previous studies suggested that external fixator systems have better outcome than plating.⁶

Correspondence :

Dr. Bhoj Raj Adhikari
Associate Professor
Department of Orthopaedics & Trauma Surgery
National Academy of Medical Sciences
Bir Hospital, Kathmandu, Nepal
Email: drbhoj62@gmail.com

Mal-union occurs more often in Volar Barton fracture and can result in considerable disability; which can be caused by failure to secure an accurate reduction. Recurrence of deformity after an accurate reduction is marked in comminution of fragments. Complete rupture of the distal radio ulnar ligaments with excessive mobility of distal ulna, failure to keep the fracture immobilized until consolidation is complete and marked crushing of fragment in elderly people with osteoporosis.⁷

In the clinical practices, various methods are used for the management of volar Barton fractures. External fixator is one of the acceptable techniques.

METHOD

This retrospective study was carried out in the department of Orthopaedics and Trauma Surgery, National Trauma Center, Kathmandu from March 2016 to September 2018. Within this period 38 patients of volar Barton fracture were selected as per inclusion and exclusion criteria who were admitted in this center.

Inclusion criteria

1. Closed Volar Barton fractures of distal radius (Association for Osteosynthesis type B and C)
2. Time less than 3 weeks
3. Age more than 18 years

Exclusion criteria

1. Open Fractures
2. Associated Infection
3. Associated fracture in ipsilateral upper limb

After proper evaluation of patients, closed reduction was done and external fixator was applied under brachial plexus block. General anaesthesia was given to those patients who failed to block. Most of the patients were discharged on third post-operative day. Dressing was changed on weekly interval. Patients were advised for range of movement of fingers and elbow as tolerated to pain. Radiographs were taken one, two and three months post-operatively to see the evidence of union. Operative outcomes were evaluated by Modified Mayo wrist score (Table 1)⁸. Radiological outcomes were evaluated as per criteria outlined by Lidstrom A and Patel SP et al^{9,10}. Minimum follow up time was 16 months from the time of surgery.

Table 1: Modified Mayo wrist score

Pain	Point
No pain	25
Mild occasional	20
Moderate	15
Severe	0
Work status	
Regular job	25
Restricted job	20
Able to work but unemployed	15
Unable to work due to pain	0
Range of motion	25
>120°	25
100 to 119°	20
90 to 99°	15
60 to 89°	10
30 to 59°	5
0 to 29°	0
Grip strength (% of normal)	
90 to 100	25
75 to 89	15
50 to 74	10
25 to 49	5
0 to 24	0

* Total point scores: excellent (91 to 100), good (80 to 90), fair (65 to 79), and poor (<64).

A normal hand should be able to achieve a reading of 200 mm Hg or over. In this study, we compared the grip strength of affected hand with normal hand.

RESULT

Out of 38 patients, 21 were male and 17 were female. Mean age was 36± 9.44 years (range 19 to 73 years). Left side involvement was more 63.16% (24 patients) than right side 36.84% (14 patients). The mode of injuries and treatment outcomes were as shown in Figure 1 and Figure 2 respectively. Two patients with superficial skin infections were treated with regular dressings. In the final follow-up according to Modified Mayo wrist score, 10 cases (26.3%) had excellent scores, 23 cases (60.5%) had good scores and 5 cases (13.2%) obtained fair scores. Functional outcomes and radiological parameters are shown in table 2.

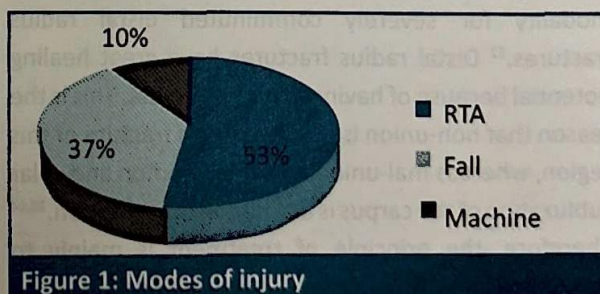


Figure 1: Modes of injury

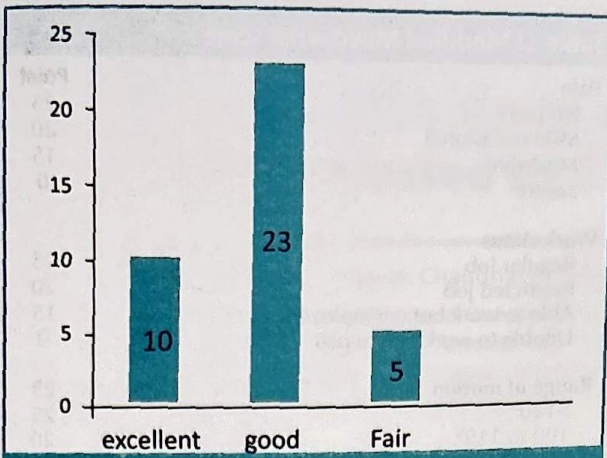


Figure 2: Treatment outcomes

Table 2: Outcomes at 12 month follow-up

	Mean
Modified Mayo wrist score	84.33 ± 8.17
Range of motion	
Extension	64.13 ± 7.47
Flexion	60.5 ± 7.18
Ulnar deviation	21.46 ± 4.7
Radial deviation	15.7 ± 4.11
Radiological parameters	
Volar tilt	5.03 ± 2.31
Radial height	9.46 ± 2.28
Radial inclination	20.13 ± 4.02
Articular step off	0.55 ± 0.38



Figure 3: X rays a) Pre-operative b) post-operative c) 6 months after operation

DISCUSSION

Bridging external fixation is a well-accepted treatment modality for severely comminuted distal radius fractures.¹² Distal radius fractures have great healing potential because of having cancellous bone. This is the reason that non-union is a rare entity in fracture of this region, whereas mal-union is not uncommon and volar subluxation of the carpus is a common presentation.^{13,14} Therefore, the principle of treatment is mainly to provide anatomic reduction and stabilization. Mal-union of volar Barton fracture is difficult to treat and can cause serious disability. In addition, the articular

cartilage may be damaged causing pain and arthritis; and articular damage cannot regenerate.^{15,16}

In our study minimum follow-up period was 16 months. Mean age of the study population was 36.0±9.3 years. Bajwa AS et al followed up 25 patients (mean age 53 years) treated with external fixator for minimum period of 2 years and concluded that distal radius fractures treated by external fixator had superior result than plating.¹⁷

In our study, 21 (55.3%) patients were male and 17 (44.7%) patients were female. This cohort was similar to that of Tahir T et al, comprising 28(57.1%) males and 21(42.9%) females.¹⁸

There were 19 (63.3%) and 11 (36.7%) patients having right and left sided involvement respectively treated by buttress plate in study done by Chaudhary P et al.¹⁹ Our study included similar 26 (63.2%) with right sided and 12 (36.8%) with left sided involvement.²⁰

In the study done by El-Adawy MF et al, 54 (77%) cases got excellent to good score and 16 (23%) cases got fair to poor score. Most of the patients returned to their pre injury activity level with a 90.7% satisfaction rate. There were 10 cases that experienced pin tract infection and were treated by antibiotics.²⁰

In our study, 33 (87%) of 38 patients had excellent to good and 5 (13%) of 38 patients had fair to poor scores. However, 90% had satisfactory functional outcomes on the basis of modified Mayo wrist score. In this study, 7% superficial skin infections were observed and were treated non-operatively.

In our study, the required mean time for bony union was 7.5±1.2 weeks. In the majority (76.6%) of the patients, time required for bony union was from 8 to 12 weeks. In a study comparing either open reduction and buttress plate fixation or closed reduction with external fixation and percutaneous Kirschner wire fixation in Volar Barton fractures, all fractures healed 3 months.²¹

CONCLUSION

The external fixator is an effective technique of fixation in displaced instable volar Barton fracture; as it maintains articular congruity, radial length and alignment.

REFERENCES

- Arora J, Malik AC. External fixation in comminuted, displaced intra-articular fractures of the distal radius: Is it sufficient?. *Arch Orthop Trauma Surg* 2005;125(8):536-540.
- Richard YK, Melvin, PR. Internal Fixation of Distal Radius Fractures. *Am J Orthop* 2007;36(12)S:2-7.
- Trumble TE, Schmitt SR, Vedder NB. Factors affecting functional outcome of displaced intra-articular distal radius fractures. *J Hand Surg Am* 1994;19(2):325-340.
- McQueen M, Hajducka C, Court-Brown CM. Redispaced unstable fractures of the distal radius: A prospective randomised comparison of four methods of treatment. *J Bone Joint Surg Br* 1996;78(3):404-409.
- Kreder HJ, Hanel DP, Agel J. Indirect reduction and percutaneous fixation versus open reduction and internal fixation for displaced intra-articular fractures of the distal radius: A randomised, controlled trial. *J Bone Joint Surg Br* 2005;87(6):829-836.
- Willis AA, Kastumi K, Zobitz ME, Cooney WP. Internal fixation of dorsally displaced fractures of the distal part the radius: A biomechanical analysis of volar plate fracture stability. *J Bone Joint Surg Br* 2006;88:2411-2417.
- Frederick MA, Canale ST, Beaty JH, editors. *Campbell's Operative Orthopedics*. 13th edition. Vol 3. Elsevier; 2017;2996-3007.
- David JS. Outcomes assessment in wrist surgery. *J Wrist Surg* 2013;2(1):1-4.
- Lidström A. Fractures of the distal end of the radius: A clinical and statistical study of end results. *Acta Orthopaedica Scandinavica* 1959; 30:S1-18.
- Patel SP, Anthony SG, Zurakowski D, et al. Radiographic scoring system to evaluate union of distal radius fractures. *J Hand Surg Am* 2014;39(8):1471-1479.
- Denby K, Nelson G, Estrada CA. Bedside hand grip assessment with the sphygmomanometer. *J Gen Intern Med* 2013; 28(10):1381.
- Lee DJ, Elfar JC. External fixation versus open reduction with locked volar plating for geriatric distal radius fractures. *Geriatr Orthop Surg Rehabil* 2014; 5(3):141-143.
- Cooney WP, Bussey R, Dobyns JH, Linscheid RL. Difficult wrist fractures. Perilunate fracture-dislocations of the wrist. *Clin Orthop Relat Res* 1987;(214):136-147.
- Harish P, Girish KK, Sudheendra PR, Harminder S. Functional results and complications of displaced intra articular distal radius fracture treated by volar plates. *Journal of Science* 2016; 6(1):1-4.
- Aggarwal AK, Nagi ON. Open reduction and internal fixation volar Barton's fractures: A prospective study. *J Ortho Surg Res* 2004;12(2):230-234.
- Mann FA, Wilson AJ, Gilula LA. Radiographic evaluation of the wrist: What does the hand surgeon want to know. *Radiology* 1992;184(1):15-24.
- Bajwa AS, Rammappa M, Lee L, Nanda R. Treatment of unstable distal radius fractures: Non-invasive dynamic external fixator versus volar locking plate – functional and radiological outcome in a prospective case-controlled series. *SICOT J* 2015;1:34.
- Tahir T, Manzoor QW, Bhat SA, Kangoo KA. Functional outcome of external fixators in unstable distal radius fractures. *Int J Orthop Sci* 2018;4(2):869-874.
- Chaudhary P, Das KP, Shrestha M, et al. Evaluation of surgical outcome of distal radius fracture (volar barton's) treated by buttress plate. *Int J Sci Res* 2020;9:45-47.
- El-Adawy MF, Henawy AT, El Haroon MS. Treatment of distal radius fractures with percutaneous pinning. *Egypt Orthop J* 2018;53:44-51.
- Dai MH, Wu CC, Liu HT, et al. Treatment of volar Barton's fractures: Comparison between two common surgical techniques. *Chang Gung Med J* 2006;29(4):388-394.