

# Anaesthetic Management for Whole Lung Lavage in Pulmonary Alveolar Proteinosis: A Case report

Ritu Pradhan<sup>1</sup>, Ravi Ram Shrestha<sup>2</sup>, Surendra Bhusal<sup>3</sup>, Nisha Khanal<sup>4</sup>, Alish Mishra<sup>4</sup>, Aminath Asma<sup>4</sup>, Nischal Gyawali<sup>4</sup>

<sup>1</sup> Associate Professor, Department of Anaesthesiology and Intensive care, NAMS, Bir Hospital

<sup>2</sup> Professor, Department of Anaesthesiology and Intensive care, NAMS, Bir Hospital

<sup>3</sup> Assistant Professor, Department of Anaesthesiology and Intensive care, NAMS, Bir Hospital

<sup>4</sup> Resident in MD anesthesiology, Department of Anaesthesiology and Intensive care, NAMS, Bir Hospital

## ABSTRACT

Pulmonary alveolar proteinosis is a rare disease in which lipoproteineous materials are deposited in the alveoli leading to impaired gas exchange and progressive hypoxaemia. Whole lung lavage is the treatment of choice. However, anaesthetic challenges like hypoxaemia, hypercarbia, hypotension during the procedure are always to be managed meticulously. Here, we describe a challenging case that underwent three sessions of whole lung lavage under general anaesthesia with endotracheal intubation with double lumen tube and one lung ventilation resulting clinical improvement in subsequent sessions.

**Key words:** anaesthesia, lung lavage, pulmonary alveolar proteinosis

## Introduction

Pulmonary alveolar proteinosis (PAP) is a rare disease where the alveoli are filled with the lipoprotein secretions, impairing the normal gaseous exchange. The progressive disease causes hypoxemia and severe respiratory failure. The etiology can be autoimmune, occupational or genetic defect. The secreted pulmonary surfactants are not cleared off the lungs due to dysfunctional granulocyte macrophages colony stimulating factor (GM-CSF). The whole lung lavage in PAP possesses anaesthetic challenges regarding oxygenation and ventilation due to the disease progression and existing hypoxaemia. This case underwent three sessions of whole lung lavage (WLL) under general anaesthesia with improvement in oxygenation.

## Case

A 30-year lady was admitted in the pulmonary intensive care unit for shortness of breath and progressive dyspnoea since three months Her pulse rate was 120 beats/min, blood pressure 120/88mmHg, respiratory rate 26/min,

afebrile and oxygen saturation 90% on 10 litres/min of oxygen via face mask with reservoir bag. Her room air oxygen saturation was below 70%. There were bilateral diffuse crepitations on chest auscultation. Her complete blood counts, platelets, renal function and liver function tests, blood glucose were within normal range. Her chest X-ray showed bilateral diffuse opacities. CT chest showed bilateral diffuse and widespread ground glass opacities with superimposed interlobular septal thickening giving "crazy paving pattern" appearance suggestive of PAP. The GM-CSF Antibody concentration was high which was suggestive of PAP. The whole lung lavage was planned under general anaesthesia. Her preoperative arterial blood gas (ABG) was PH-7.45, PaO<sub>2</sub>-60mmHg, PaCO<sub>2</sub>-42mmHg, FiO<sub>2</sub>-90%, HCO<sub>3</sub><sup>-</sup>-24mmHg with high A-a gradient (>400mmHg).

Intravenous access was opened with 18G cannula. The routine ASA standard monitors: ECG, Noninvasive blood pressure, Pulseoximeter, capnography, temperature along with invasive arterial line in left radial artery and urinary catheter were placed. Preoxygenation was done with 100% oxygen and CPAP 10cmH<sub>2</sub>O for 5min in propped up position. She was induced with fentanyl 100mcg, titrating dose of Propofol 100mg and succinylcholine 100mg. Endotracheal intubation with double lumen tube (DLT) 35Fr left side was confirmed by auscultation and flexible pediatric bronchoscope. Anaesthesia was maintained with sevoflurane, 100%oxygen and pressure control ventilation. Left sided whole lung lavage was performed. One litre of

## Correspondence:

Ritu Pradhan,  
Department of Anaesthesiology and Intensive care, NAMS,  
Bir Hospital, Mahabouddha, Kathmandu, Nepal  
Email: ritupn66@gmail.com

## Anaesthetic Management for Whole Lung Lavage in Pulmonary Alveolar Proteinosis: A Case report

normal saline was infused in first cycle followed by five minutes of chest physiotherapy (percussion) and the saline was drained out. The position was maintained as head up and left lateral tilt during saline instillation to prevent spillage in right lung and trendelenburg, left lateral tilt during drainage out. Ten cycles of the lung wash was performed with around six litres of normal saline till milky effluent drained fluid was more clear. It took two hours and 40 minutes with positive balance of 340ml and urine output of 500ml. During the procedure, there were episodes of desaturation down to 70% which was managed with both lung ventilation, PEEP, 100% oxygen and manual bagging and saturation maintained at 85-90%. Lung compliance, peak airway and plateau pressures were also monitored. At the end of the procedure, DLT was exchanged with the single lumen tube with subglottic suction size 7 mmID and lung recruitment was done. Inj Furosemide 20mg was given. Patient was kept in mechanical ventilation in airway pressure release ventilation mode with muscle relaxant and fentanyl sedation. Postoperative ABG and chest X-ray were sent. She was extubated next day and could maintain oxygen saturation of 90-92% with FiO<sub>2</sub> of 0.9 which could be tapered to 0.6 after two days.

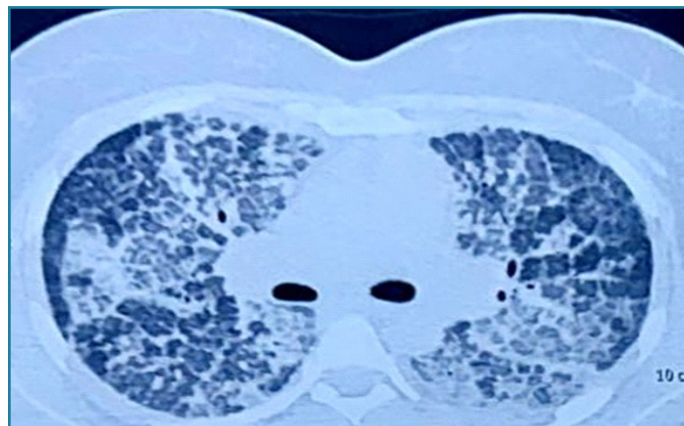


**Fig 1:** Milky effluent fluid becoming more clear in subsequent lavages shown in numbered bottles

The second session of the left WLL was done after 2 weeks. Total 14 litres of normal saline wash was performed in 14 cycles with around positive balance of 1700ml, urine output 1400ml over a period of three hours. The oxygen saturation was maintained between 88%- 95%. She was extubated next day and maintaining saturation of 96% with FiO<sub>2</sub> of 0.4.

After six weeks, the third lavage was performed in right lung with 10 litres of normal saline in 10 cycles. Her preoperative ABG was PH 7.45, PaO<sub>2</sub> 47mmHg, PaCO<sub>2</sub> 40mmHg, HCO<sub>3</sub> 29mmHg, SaO<sub>2</sub> 92%, A-a gradient 47mmHg in FiO<sub>2</sub> 0.24. Oxygen saturation was maintained at 90-95% with stable hemodynamics. Confirmation of no air leak in left lung was performed by ensuring no air bubble from left lumen of DLT during the ventilation of right side before the procedure. Postprocedure mechanical ventilation in PCV mode with single lumen tube was continued and extubated the next day. She was more comfortable than previous lavages and maintaining saturation 98% in FiO<sub>2</sub> of

0.4 tapered to 0.24. She was discharged home after one week.



**Fig 2:** CT scan of pulmonary alveolar proteinosis showing opacities "crazy paving pattern"

## Discussion

The whole lung lavage is the main treatment for PAP. It was first described by Juan Ramirez Rivera. Hypoxaemia, hypercarbia, fever, difficulties with one lung ventilation, unstable hemodynamics, contralateral fluid leakage, pneumothorax are some of the complications challenging the anaesthesiologists. In this case, the anaesthetic challenges were intraoperative desaturation, hypercarbia, reduce compliance with high airway pressure and hypotension in the first session. Desaturation was managed by both lung ventilation with 100% oxygen and applying PEEP. CPAP preoxygenation done in this case was helpful to maintain oxygenation saturation during induction. Application of CPAP in lavage lung during drainage is another option for hypoxemia prevention during the procedure. In the next sessions, there was hypercarbia which was successfully managed with the post procedure mechanical ventilation. Regarding the anaesthetic procedure, general anaesthesia was preferred as in other case reports also. Total Intravenous agent (TIVA) or inhalational agent was used for the maintenance of anaesthesia in the literatures. TIVA preserves hypoxic pulmonary vasoconstriction. Left sided DLT is preferred to avoid the difficulties of Right sided tube. In this case also, left sided tube was kept. The temperature was maintained with the warm normal saline for wash and forced air warming blanket covering the patient. There were episodes of desaturations during drainage phase and improvement of saturation during saline infusion due to the decrease in shunt fraction during instillation of fluid and increase in shunt fraction during the drainage phase.

Semi lateral position was done in this case. The dependent lung was lavaged to prevent the flooding of the ventilated

lung. Lateral, semi lateral and supine, all the positions have been mentioned in the literature. The most infected lung is lavage first but in case both the lungs are affected, left lung is lavaged first as also done in this case. However, there is always risk of spillage of fluid in the ventilated lung causing increased airway pressure, ventilation perfusion mismatch and hypercarbia. The first lavage was challenging as patient was severe hypoxemic further complicated by spillage on ventilated lung which could be successfully managed in this case. In subsequent sessions, she has gradual clinical and functional improvement.

The multidisciplinary approach between the anesthesiologists, pulmonologists, intensivists and the respiratory therapists with team spirit is required for the successful management of the PAP.

### Declaration

The patient has given written informed consent for publication in a scientific journal and has been informed that the direct identity will not be disclosed. However, complete anonymity cannot be guaranteed as it is possible somebody (caregiver or relative/friend) may recognize the patient from the information published in the journal.

### Conflict of Interest

None

### References

1. Shah PL, Hansell D, Lawson PR, Reid KB, Morgan C. Pulmonary alveolar proteinosis: Clinical aspects and current concepts on pathogenesis. *Thorax* 2000;55:6777  
DOI: [10.1136/thorax.55.1.67](https://doi.org/10.1136/thorax.55.1.67)  
PMID: 10607805 PMCID: PMC1745595
2. Hunter Guevara LR, Gillespie SM, Klompas AM, Torres NE, Barbara DW. Whole-lung lavage in a patient with pulmonary alveolar proteinosis. *Ann Card Anaesth* 2018;21:215-7  
DOI: [10.4103/aca.ACA\\_184\\_17](https://doi.org/10.4103/aca.ACA_184_17)  
PMID: 29652291 PMCID: PMC5914230
3. Ramirez, J H, Rebecca B. Schultz and Robert E. Dutton. "pulmonary alveolar proteinosis: a new technique and rationale for treatment." *Archives of internal medicine*.1963;112: 419-31.  
DOI: [10.1001/archinte.1963.03860030173021](https://doi.org/10.1001/archinte.1963.03860030173021)  
PMID: 14045290
4. Hunter Guevara LR, Gillespie SM, Klompas AM, Torres NE, Barbara DW. Whole-lung lavage in a patient with pulmonary alveolar proteinosis. *Ann Card Anaesth*. 2018 Apr-Jun;21(2):215-217.  
DOI: [10.4103/aca.ACA\\_184\\_17](https://doi.org/10.4103/aca.ACA_184_17)  
PMID: 29652291 PMCID: PMC5914230
5. Rebelo HM, Guedes L, Veiga D, Fiuza AC, Abelha F. Anaesthetic, procedure and complications management of serial whole-lung lavage in an obese patient with pulmonary alveolar proteinosis: case report. *Rev Bras Anesthesiol* 2012;62:869-77  
DOI: [10.1016/S0034-7094\(12\)70187-3](https://doi.org/10.1016/S0034-7094(12)70187-3)  
PMID: 23176995
6. Pandit A, Gupta N, Madan K, Bharti SJ, Kumar V. Anaesthetic considerations for whole lung lavage for pulmonary alveolar proteinosis. *Ghana Med J*. 2019 Sep;53(3):248-251.  
DOI: [10.4314/gmj.v53i3.9](https://doi.org/10.4314/gmj.v53i3.9)  
PMID: 31741497 PMCID: PMC6842735
7. Tan Z; TanKT . Anesthetic Management for Whole Lung Lavage in Patients with Pulmonary Alveolar Proteinosis. *A & A Case Reports*.2016; 6(8): 234-237.  
DOI: [10.1213/XAA.0000000000000283](https://doi.org/10.1213/XAA.0000000000000283)  
PMID: 26795910
8. Campo I, Luisetti M, Griese M, Trapnell BC, Bonella F, Grutters J, Nakata K, Van Moorsel CH, Costabel U, Cottin V, Ichiwata T, Inoue Y, Braschi A, Bonizzoni G, Iotti GA, Tinelli C, Rodi G; WLL International Study Group. Whole lung lavage therapy for pulmonary alveolar proteinosis: a global survey of current practices and procedures. *Orphanet J Rare Dis*. 2016 Aug 31;11(1):115.  
DOI: [10.1186/s13023-016-0497-9](https://doi.org/10.1186/s13023-016-0497-9)  
PMID: 27577926 PMCID: PMC5006612
9. Abdelmalak BB, Khanna AK, Culver DA, Popovich MJ. Therapeutic Whole-Lung Lavage for Pulmonary Alveolar Proteinosis: A Procedural Update. *J Bronchology Interv Pulmonol*. 2015 Jul;22(3):251-8.  
DOI: [10.1097/LBR.0000000000000180](https://doi.org/10.1097/LBR.0000000000000180)  
PMID: 26165897
10. Silva A, Moreto A, Pinho C, Magalhes A, Morais A, Fiuza C. Bilateral whole lung lavage in pulmonary alveolar proteinosis-A retrospective study. *Rev Port Pneumol*. 2014;20(5):254-259  
DOI: [10.1016/j.rppneu.2014.04.004](https://doi.org/10.1016/j.rppneu.2014.04.004)  
PMID:25042291